

Journal Pre-proof

Bariatric stamp

L. Taboada Paz E. Vicente Basanta MM. Otero Rivas

PII: S0001-7310(25)00780-X


DOI: <https://doi.org/doi:10.1016/j.ad.2025.104511>

Reference: AD 104511

To appear in: *Actas dermosifiliograficas*

Received Date: 8 January 2024

Accepted Date: 24 February 2024



Please cite this article as: Taboada Paz L, Vicente Basanta E, Otero Rivas M, Bariatric stamp, *Actas dermosifiliograficas* (2025), doi: <https://doi.org/10.1016/j.ad.2025.104511>

This is a PDF of an article that has undergone enhancements after acceptance, such as the addition of a cover page and metadata, and formatting for readability. This version will undergo additional copyediting, typesetting and review before it is published in its final form. As such, this version is no longer the Accepted Manuscript, but it is not yet the definitive Version of Record; we are providing this early version to give early visibility of the article. Please note that Elsevier's sharing policy for the Published Journal Article applies to this version, see: <https://www.elsevier.com/about/policies-and-standards/sharing#4-published-journal-article>. Please also note that, during the production process, errors may be discovered which could affect the content, and all legal disclaimers that apply to the journal pertain.

© 2025 Published by Elsevier España, S.L.U. on behalf of AEDV.

Sección: Caso para Diagnóstico**Bariatric stamp****Authors:**

L. Taboada Paz, E. Vicente Basanta, M. M. Otero Rivas

Servicio de Dermatología. Complejo Hospitalario Universitario de Ferrol. Ferrol (A Coruña, Spain)

Corresponding author

Laura Taboada Paz.

E-mail address: laurataboadapaz@gmail.com

Case Presentation

A 31-year-old woman presented with a 4-month history of persistent, asymptomatic pigmentation on the buttocks. Her past medical history included knee arthroscopy 3 years prior and gastric bypass surgery 1 year prior.

Dermatologic examination revealed brown-gray, ill-defined plaques with figured borders located on the posterolateral aspects of both buttocks (Figures 1–3). No other cutaneous or mucosal lesions were identified.

The initial differential diagnosis included the following possibilities: a complication following a cosmetic procedure, vitamin K–deficiency–related postoperative ecchymoses, incompletely treated laser tattoos, post-inflammatory hyperpigmentation, McCune-Albright syndrome, among others. However, after detailed questioning, it was discovered that the patient had been receiving intramuscular iron supplementation for iron-deficiency anemia for the past 5 months, and the lesions had appeared progressively after approximately 20 injections.

Diagnosis and Comments**Diagnosis**

Cutaneous siderosis.

Comments

Regarding the differential diagnosis, we ruled out ecchymosis at the injection site because the lesions exhibited a homogeneous appearance from their onset and did not resolve spontaneously. Although a biopsy was not performed, it is worth noting that histopathology would not have been helpful, as extravascular hemosiderin deposition would be seen regardless of whether the source was traumatic hemorrhage at the injection site or iron extravasation.

The prevalence of obesity has risen steadily in recent years. This epidemic has led to a substantial increase in bariatric procedures and, consequently, their complications.¹ Among bariatric techniques, gastric bypass is categorized as a malabsorptive procedure. These techniques include nutritional deficiencies among their potential postoperative complications.

In gastric bypass, the proximal small intestine is excluded; therefore, patients may develop deficiencies in nutrients absorbed in this portion of the gut. Iron is absorbed primarily in the duodenum, explaining the high risk of iron-deficiency anemia in this population. Consequently, many of these patients require iron supplementation, which must be administered intramuscularly to bypass impaired GI absorption.

Siderosis is defined as the accumulation of iron in various tissues. Cutaneous siderosis is a relatively common adverse effect after parenteral iron administration²³; however, few cases have been reported as a complication of intramuscular iron injection.⁴⁵

Dermatologic diagnosis can pose a significant challenge when key clinical information is not obtained during the patient interview or when the patient or family members do not provide sufficient detail.

We propose the term “**bariatric stamp**” as a clinical sign that may aid in identifying cutaneous siderosis resulting from intramuscular iron injections in patients with anemia after bariatric surgery.

References

Bibliografía

- [1] Kassir, R., Debs, T., Blanc, P., Gugenheim, J., Ben Amor, I., Boutet, C., & Tiffet, O. (2016). Complications of bariatric surgery: Presentation and emergency management. *International journal of surgery (London, England)*, 27, 77–81. <https://doi.org/10.1016/j.ijssu.2016.01.067>
- [2] Shi, R., Marin, J. G., & Beaulieu, M. (2023). Skin Staining Following Intravenous Iron Extravasation in a Patient With Chronic Kidney Disease: A Case Report. *Canadian journal of kidney health and disease*, 10, 20543581231165705. <https://doi.org/10.1177/20543581231165705>
- [3] Serra, J. P. S., Liñán, A. G., & Martínez, J. R. (2023). Un tatuaje iatrogénico. *Actas Dermo-Sifiliográficas*, 114(9), 829. <https://doi.org/10.1016/j.ad.2022.05.040>
- [4] Ozlu, E., Karadag, A. S., Bilgili, S. G., & Bayram, I. (2014). Cutaneous siderosis after intramuscular iron injections: a case report. *Cutaneous and ocular toxicology*, 33(4), 348–350. <https://doi.org/10.3109/15569527.2013.875558>
- [5] Bork K. (1984). Lokalisierte kutane Siderose nach intramuskulären Eiseninjektionen [Localized cutaneous siderosis following intramuscular iron injections]. *Der Hautarzt; Zeitschrift für Dermatologie, Venerologie, und verwandte Gebiete*, 35(11), 598–599.

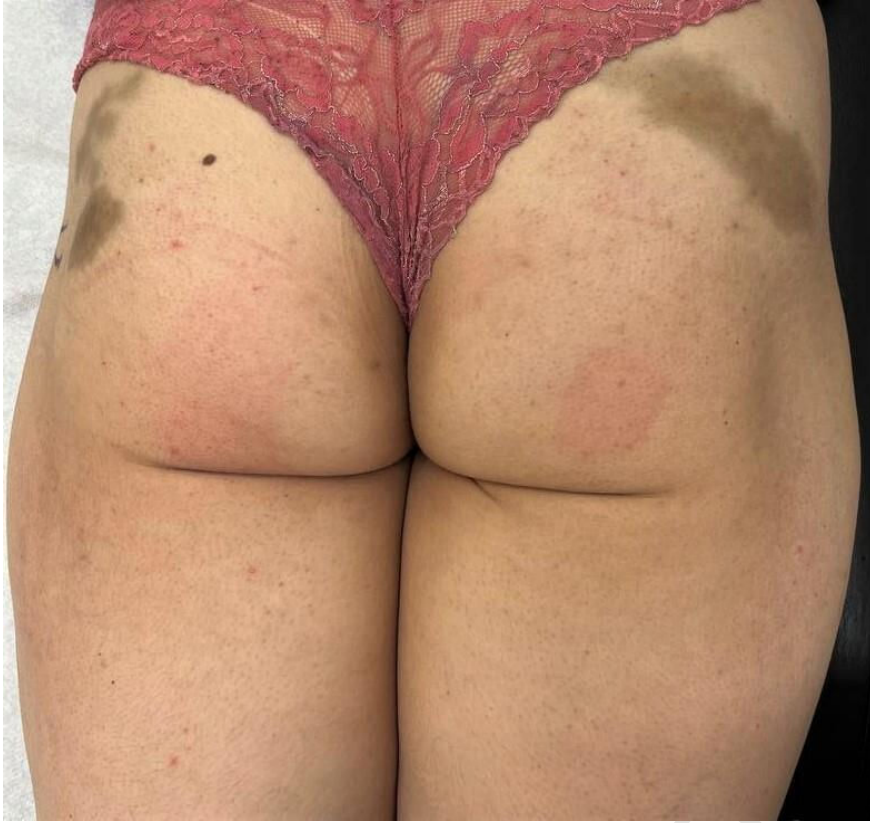

Figure 1.

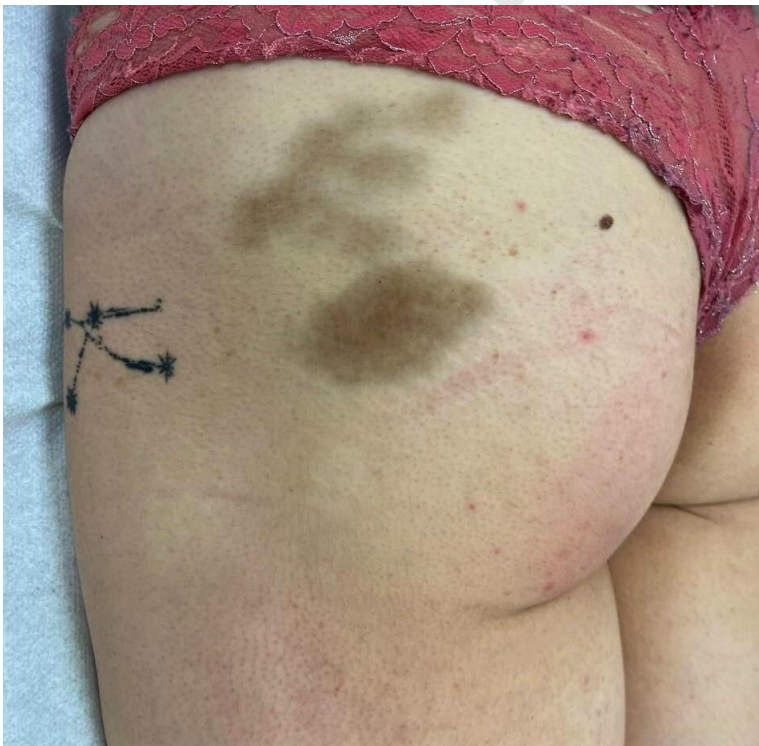

Figure 2.

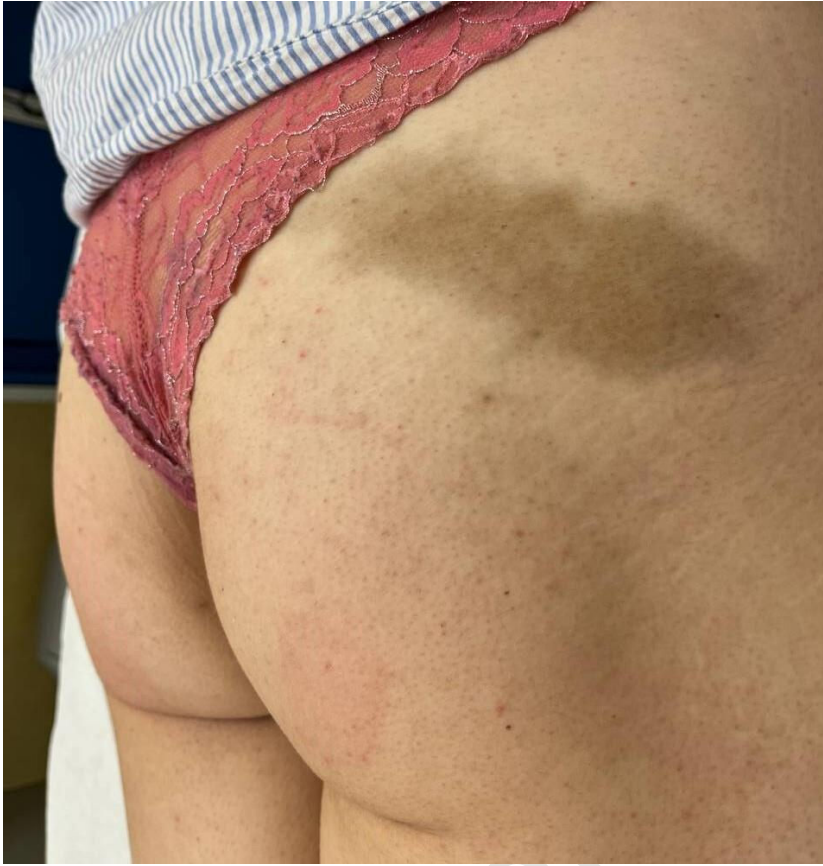

Figure 3.