

## Challenging Case

**Cutaneous Squamous Cell Carcinoma While on Vismodegib Therapy for Locally Advanced Basal Cell Carcinoma**

## Case report

**Q2** A 61-year-old woman with no significant past medical history presented in April 2022 with bleeding from a dorsolumbar lesion (Fig. 1A) that had been present for 10 years. Biopsy revealed an infiltrating basal cell carcinoma (BCC) (Fig. 1B–C). The patient was hospitalized due to severe, disabling low back pain. MRI of the thoracolumbar spine revealed the presence of a 11 cm × 2.8 cm × 5 cm tumor at the level of the L1–L2 intervertebral space, with compression of the cauda equina roots and infiltration of the left paravertebral musculature and left psoas muscle.

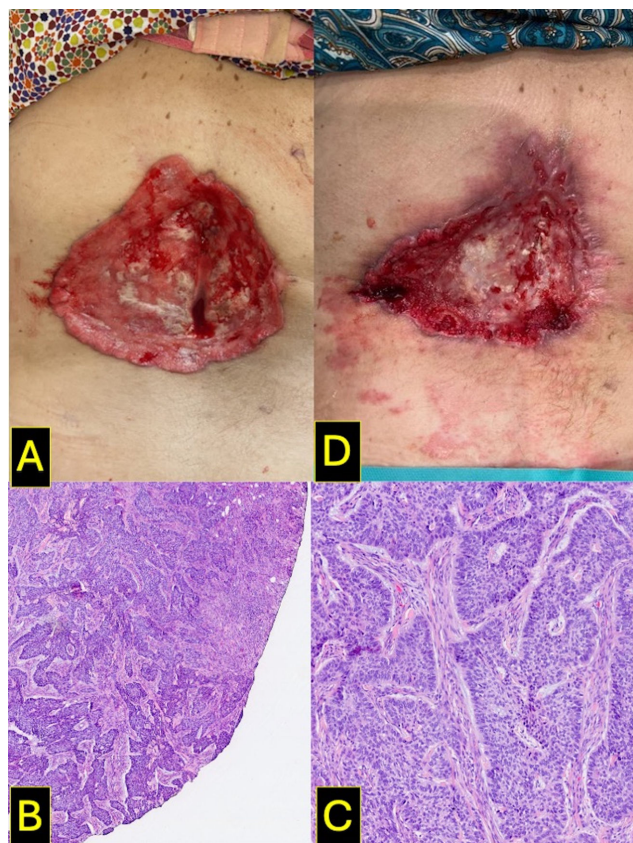


Fig. 1.

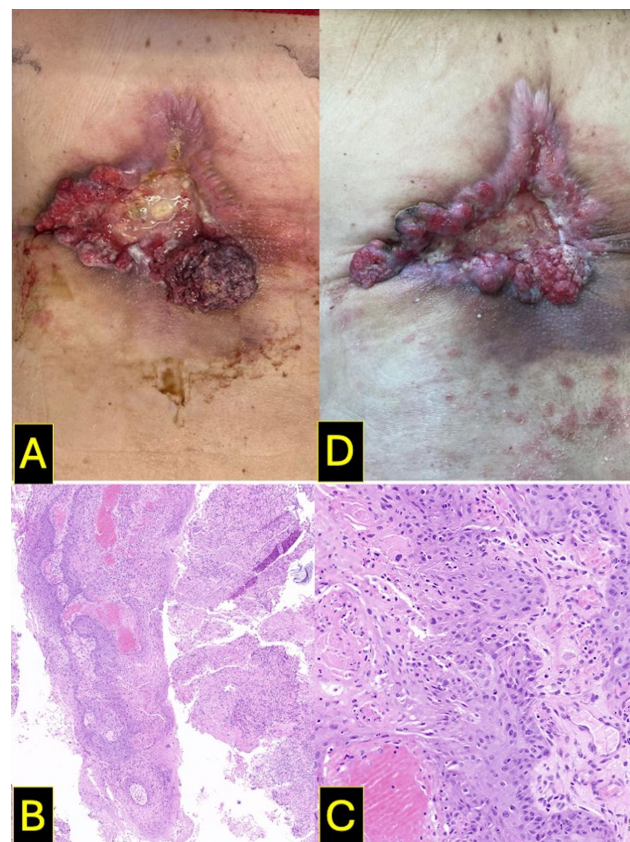


Fig. 2.

The case was staged as locally advanced BCC, stage IIIA (EADO classification), not amenable to surgery or radiotherapy. Treatment with vismodegib (150 mg/day orally) was initiated in May 2022. An initial clinical improvement was observed (Fig. 1D, October 2022), which persisted until February 2023, when the patient experienced worsening pain and a newly developed mass at the lower right margin of the original lesion (Fig. 2A). Biopsy of the new lesion confirmed infiltrating cutaneous squamous cell carcinoma (SCC) (Fig. 2B–C). The case was reported to the Spanish Pharmacovigilance System, and pembrolizumab therapy was initiated. After 4 months into therapy, the patient showed clinical improvement (Fig. 2D), with reduced analgesic requirements and no relevant toxicity.

What is your diagnosis?

<https://doi.org/10.1016/j.ad.2025.104500>

0001-7310/© 2025 AEDV. Published by Elsevier España, S.L.U. This is an open access article under the CC BY-NC-ND license (<http://creativecommons.org/licenses/by-nc-nd/4.0/>).

Please cite this article as: B. Sánchez Lafuente, P.J. Vera García and P. Cerezuela Fuentes, Cutaneous Squamous Cell Carcinoma While on Vismodegib Therapy for Locally Advanced Basal Cell Carcinoma, ACTAS Dermo-Sifiliográficas, <https://doi.org/10.1016/j.ad.2025.104500>

## Diagnosis and comments

Vismodegib is a hedgehog pathway inhibitor approved by the Spanish Agency for Medicines and Health Products (AEMPS) in August 2013 for the treatment of locally advanced and metastatic BCC.

Although the development of SCC within the tumor bed of a BCC is a rare finding, it has nonetheless been documented. In animal models, downregulation of hedgehog signaling predisposes to SCC formation.<sup>1</sup> Furthermore, vismodegib may promote a shift toward squamous differentiation and keratinization in responsive patients.<sup>2</sup> Several cases of SCC associated with vismodegib use have been reported, both in distant sites and within the tumor bed of the treated BCC.<sup>3</sup> In this report, we describe a clinically significant case of SCC developing in the bed of a locally advanced BCC following initiation of vismodegib therapy. The initial biopsy only showed basal cell histologic features, without evidence of squamous differentiation (Fig. 1B). A case-control study demonstrated a > 6-fold increased risk of developing non-BCC tumors within the same lesion in patients on vismodegib.<sup>4</sup>

Several hypotheses have been proposed for vismodegib-induced SCC, including selection of a preexisting SCC subpopulation; induction of squamous differentiation in malignant basal cells due to hedgehog pathway changes; and activation of the RAS/MAPK pathway due to SMO inhibition, which eliminates hedgehog pathway dependence for tumorigenesis. This process may allow surrounding epidermal cells, already carrying UV-induced mutational burdens, to undergo malignant transformation, with hedgehog pathway inhibition serving as the initiating event.<sup>4–6</sup>

The features of previously reported cases<sup>3,5,6</sup> are shown in Table 1. Because of their observational nature and difficulty in quantifying UV- or radiation-induced field cancerization, a causal relationship cannot be definitively established. However, the temporal association between vismodegib initiation and subsequent SCC development suggests a possible link, warranting close dermatologic surveillance during therapy with vismodegib. To date, no SCCs have been reported in patients on sonidegib, another hedgehog pathway inhibitor approved for locally advanced BCC. Nonetheless, close monitoring is advisable for patients on this therapy and repeat biopsy should be considered for any lesion that fails to resolve or shows new proliferation.<sup>5</sup> In some cases, local

excision may be sufficient to treat the new SCC. In the present case, treatment was switched to an anti-PD-1 agent (pembrolizumab) due to concerns regarding the feasibility of complete surgical resection.

## Conflict of interest

The authors declare that they have no conflict of interest.

## References

1. Wakabayashi Y, Mao J-H, Brown K, Girardi M, Balmain A. Promotion of Hras-induced squamous carcinomas by a polymorphic variant of the Patched gene in FVB mice. *Nature*. 2007;445:761–765.
2. Bancalari B, Llombart B, Serra-Guillén C, et al. Histologic changes during treatment with vismodegib in locally advanced basal cell carcinoma: a series of 19 cases. *Am J Dermatopathol*. 2019;41:711–717, <http://dx.doi.org/10.1097/DAD.0000000000001384>. PMID: 31436575.
3. Zhu GA, Sundram U, Chang ALS. Two different scenarios of squamous cell carcinoma within advanced basal cell carcinomas. Cases illustrating the importance of serial biopsy during vismodegib usage. *JAMA Dermatol*. 2014;150:970–973.
4. Mohan SV, Chang J, Li S, Henry AS, Wood DJ, Chang ALS. Increased risk of cutaneous squamous cell carcinoma after vismodegib therapy for basal cell carcinoma. *JAMA Dermatol*. 2016;152:527–532.
5. Saintes C, Saint-Jean M, Brocard A, et al. Development of squamous cell carcinoma into basal cell carcinoma under treatment with vismodegib. *J Eur Acad Dermatol Venereol*. 2015;29:1006–1009.
6. Zhao R, Wang B, Lowe L, Dlugosz A, Bichakjian CK. Metastatic same-site squamous cell carcinoma arising during vismodegib therapy for basal cell carcinoma. *JAAD Case Rep*. 2022;28:54–57.

B. Sánchez Lafuente <sup>a,\*</sup>, P.J. Vera García<sup>b</sup>, P. Cerezuela Fuentes<sup>a</sup>

<sup>a</sup> Servicio de Oncología Médica, Hospital Clínico Universitario Virgen de la Arrixaca, Carretera de Madrid-Cartagena s/n, 30120 El Palmar, Murcia, Spain

<sup>b</sup> Servicio de Cirugía Plástica y Quemados, Hospital Clínico Universitario Virgen de la Arrixaca, Carretera de Madrid-Cartagena s/n, 30120 El Palmar, Murcia, Spain

\* Corresponding author.

E-mail address: [bslaf1902@gmail.com](mailto:bslaf1902@gmail.com) (B. Sánchez Lafuente)