




ACTAS Derma-Sifiliográficas

Full English text available at
www.actasdermo.org



CASE REPORT

Localized Pemphigus Foliaceus with Unilateral Facial Involvement

A.D. Maderal, A. Miner, C. Nousari, J. Alonso-Llamazares*

Department of Dermatology and Cutaneous Surgery, University of Miami Miller School of Medicine, Miami, FL, USA

KEYWORDS

Pemphigus foliaceus;
Localized;
Bullous disorders

PALABRAS CLAVE

Pénfigo foliáceo;
Localizado;
Enfermedades
ampollosas

Abstract Pemphigus foliaceus is a superficial vesiculobullous disease that typically presents with widespread lesions. Localized presentations are less frequent, and they typically occur in middle-aged patients, following exposure to topical medications, and later on, become more disseminated. We present a case of a 19-year-old female with a localized presentation of pemphigus foliaceus unrelated to previous topical medications, that was a diagnostic and therapeutically challenging case. We also discuss the literature on localized cases, differences in presentations and responses to various treatment modalities.

© 2012 Elsevier España, S.L. and AEDV. All rights reserved.

Pénfigo foliáceo localizado con afectación facial unilateral

Resumen El pénfigo foliáceo es una enfermedad vesículo-ampollosa superficial caracterizada por la aparición de lesiones generalizadas. Las presentaciones localizadas son menos frecuentes y suelen observarse en pacientes de mediana edad tras la exposición a medicamentos tópicos que posteriormente evolucionan a formas más diseminadas. Presentamos el caso de una mujer de 19 años de edad con pénfigo foliáceo localizado no asociado a medicamentos tópicos previos cuyo diagnóstico y tratamiento han supuesto un reto. También analizamos la literatura existente sobre los casos de pénfigo foliáceo localizado, las diferencias en las presentaciones clínicas y las respuestas a distintos tipos de tratamientos.

© 2012 Elsevier España, S.L. y AEDV. Todos los derechos reservados.

Introduction

Pemphigus foliaceus (PF) is a superficial vesiculobullous disease characterized by production of IgG4 antibodies targeting desmoglein 1, a protein important for epidermal cell–cell adhesion.^{1,2} Disruption of cell–cell adhesion causes

acantholysis resulting in superficial, fragile blisters that are prone to rupture. Consequently, patients typically present with erosions rather than blisters.³ Typically, the lesions are well-demarcated and occur on the face or trunk. They tend to be disseminated, and localized presentations are rare. The incidence of PF varies between different populations, and the average age of onset is between 50 and 60 years.³ The pathogenesis of PF is not completely understood, but environmental exposure appears to be involved.^{2,4,5} We present an interesting case of a young woman with a difficult-to-treat, localized form of PF that was unrelated to any known triggers.

* Corresponding author.
E-mail addresses: jalonso2@med.miami.edu,
alonso.javier1@gmail.com (J. Alonso-Llamazares).

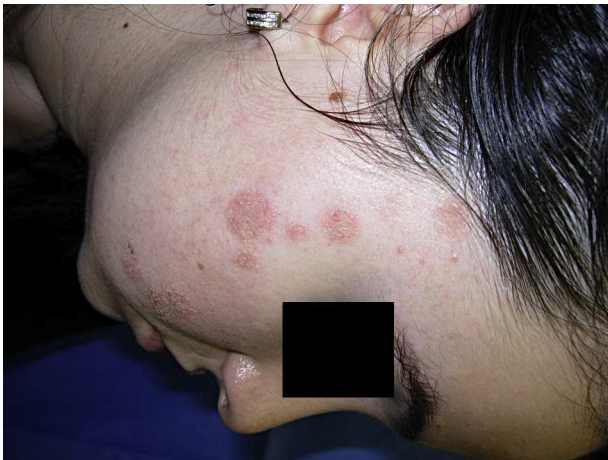

Figure 1 Faint erythematous and eroded impetiginized patches on the right cheek and temple.

Clinical case

The patient was a 19-year-old Cuban-American woman who presented to our clinic with a 6-month history of eroded, erythematous, crusted lesions on the right side of her face. The lesions had been treated unsuccessfully with topical antifungals, antibiotics, and oral antibiotics for a presumed diagnosis of tinea or impetigo. The patient had no significant past medical history, and her only medications included oral contraceptives and occasional ibuprofen.

A physical examination revealed faint erythematous, eroded impetiginized patches on the right cheek and temple (Fig. 1). A culture from 1 lesion grew methicillin-sensitive staphylococcus aureus. Further laboratory studies were undertaken to screen for antinuclear antibodies, including anti-double-stranded DNA antibodies, and antibodies against the extractable nuclear antigens Smith, Ro, and La, and the histone proteins; the results were negative in all cases. A biopsy revealed superficial acantholysis and hyperchromatic nuclei in the granular layer, consistent with PF. Direct immunofluorescence studies demonstrated segmental intercellular staining with immunoglobulin (Ig) G and C3 (Fig. 2a and b). Enzyme-linked immunosorbent assay (ELISA) was negative for desmogleins 1 and 3. Based on these results, a diagnosis of PF was confirmed and the patient was started on clobetasol propionate 0.05% ointment with partial response. A trial of dapsone 100 mg daily for 2 months resulted in no benefit. Prednisone 60 mg daily with gradual taper induced clinical remission with no relapse during a follow-up of 18 months, except for a recent development of a single erythematous patch on the right cheek with confirmation of PF by direct immunofluorescence testing.

Localized PF is rare, and only 12 cases have been reported in the literature (Table 1)^{4,6-12}; moreover, some of these cases later developed widespread lesions.^{6,7,12} Topical medications, such as imiquimod and nonsteroidal anti-inflammatory drugs, have been implicated in localized PF (Table 1).^{4,5} In contrast, to other cases reported, our patient was younger, she denied application of any topical medications, and the lesions did not become disseminated.

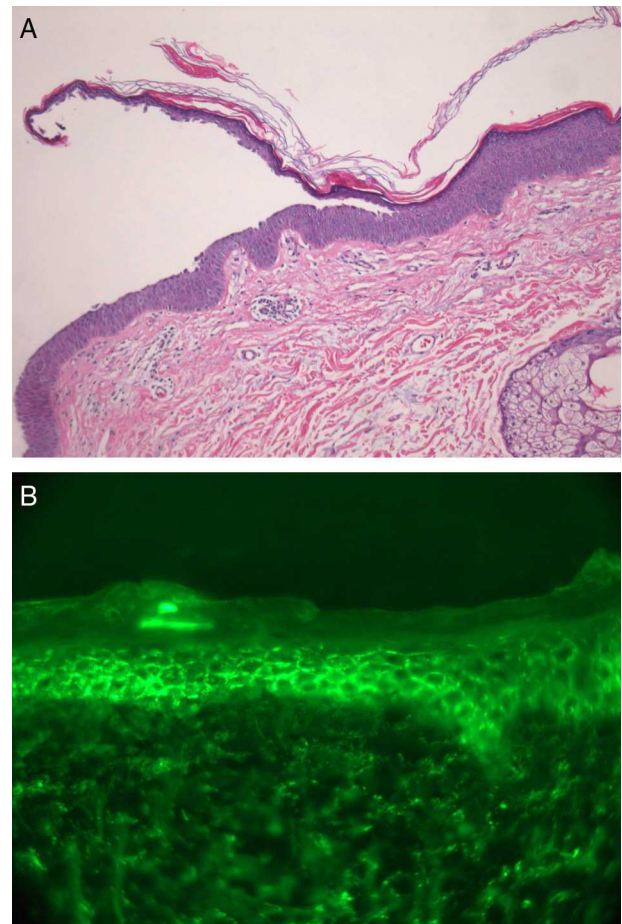


Figure 2 (a) Superficial acantholysis and hyperchromatic nuclei in the granular layer (hematoxylin–eosin, original magnification $\times 20$) and (b) DIF at $40\times$ magnification displaying segmental intercellular staining for IgG and C3.

Despite the clinical impression of impetigo, the lack of response to appropriate antibiotic treatment and the persistence of the lesions prompted us to suspect an immunobullous disorder as the source of the secondarily impetiginized lesions. The presence of subcorneal acantholysis and intercellular staining demonstrated by direct immunofluorescence confirmed the diagnosis of PF: the histopathological features of bullous impetigo may be similar to those of PF, but immunopathology would be negative in bullous impetigo.² In PF, ELISA testing of anti-desmoglein-1 antibodies is usually positive, with sensitivities as high as 97.9%,¹³ and this test has been found to have greater sensitivity and specificity than conventional indirect immunofluorescence (IIF).¹⁴ A positive ELISA was reported in two of the published cases of localized PF, and IIF results in these cases were variable (see Table 1). Interestingly, our patient had a negative ELISA but IIF results were positive.

With regard to management, topical steroids may be used for more localized lesions (see Table 1) but systemic steroids are currently the mainstay of treatment and were required in our patient to induce clinical remission.¹⁵ Other treatments, such as dapsone, failed in our case.

In conclusion, immunobullous disease should be suspected in presumed infectious disorders that are

Table 1 Previous reported cases of localized pemphigus foliaceus.

Author	Age	Location of lesions	Presumed triggers	Pathology findings	DIF, IIF, and/or ELISA	Therapy and response	Dissemination
Newton et al. ⁶	27	Left side of nose	ND	Subcorneal bulla with considerable acantholysis	<ul style="list-style-type: none"> • <i>DIF</i>: intercellular IgG and C3 • <i>IIF</i>: positive 	Unresponsive to topical steroids	No
	62	Nose	ND	Acantholysis in granular layer	<ul style="list-style-type: none"> • <i>DIF</i>: intercellular C3 • <i>IIF</i>: positive at a titre of 1:320 	Unresponsive to topical steroids; controlled with cyclophosphamide	Yes
	43	Nose	ND	N/A	N/A	Oral prednisone 5–15 mg/d prevented relapse	N/A
Paramsothy et al. ⁷	34	Tip of nose, external nares and nasolabial fold	ND	Subcorneal blister which was partially intra- and partially infra-granular with acantholytic cells	<ul style="list-style-type: none"> • <i>DIF</i>: IgG between epidermal cells • <i>IIF</i>: positive at a titre of 1:40 	Prednisolone 30 mg/day cleared rash but discontinued due to side effects	Yes
	65	Nose and behind left ear	ND	Intraepidermal bulla formation below the granular layer; marked acantholysis	<ul style="list-style-type: none"> • <i>DIF</i>: IgG between epidermal cells and granular IgM in basement membrane • <i>IIF</i>: negative 	Lesions improved after topical clobetasol propionate	N/A
Yamamoto et al. ⁸	81	Right cheek	ND	Intraepidermal cleft in granular layer and acantholytic cells within the cleft	<ul style="list-style-type: none"> • <i>DIF</i>: IgG in intercellular spaces of upper cell layers • <i>IIF</i>: negative 	Received minocycline 100 mg daily, nicotinamide 9.0 g daily and betamethasone valerate 2.0 g daily; lesion cleared in 14 days	No
Termeer et al. ⁹	83	Scalp	Appeared following small local injury	Split in upper granular layer of epidermis and superficial bulla filled with acantholytic keratinocytes and fibrin	<ul style="list-style-type: none"> • <i>DIF</i>: IgG in upper epidermal layers 	Treated with tacrolimus 0.1% twice daily and it significantly improved after 1 month	No
Lin et al. ⁴	53	Left side of face	Topical 5% imiquimod cream	Superficial acantholytic vesicular dermatitis	<ul style="list-style-type: none"> • <i>DIF</i>: IgG at keratinocyte cell surface in granular layer 	IM 0.1% TAC and topical clobetasol propionate resulted in improvement, required oral prednisone to maintain clinical remission	No

Table 1 (Continued)

Author	Age	Location of lesions	Presumed triggers	Pathology findings	DIF, IIF, and/or ELISA	Therapy and response	Dissemination
Kishibe et al. ¹⁰	63	Tip of nose	ND	Subcorneal acantholysis, especially of follicular infundibulum	<ul style="list-style-type: none"> • <i>DIF</i>: IgG deposition • <i>IIF</i>: negative • <i>ELISA</i>: negative for anti-desmogleins 1 and 3 antibodies 	Responded to oral prednisolone 40 mg daily	No
Zaraa et al. ¹¹	42	Scalp	ND	Acantholytic cells were present	<ul style="list-style-type: none"> • <i>DIF</i>: positive • <i>IIF</i>: positive • <i>ELISA</i>: positive for anti-desmoglein 1 antibodies 	Topical clobetasol propionate and infiltration of triamcinolone acetonide resulted in complete healing	No
	34	Right cheek	ND	Acantholytic cells were present	<ul style="list-style-type: none"> • <i>DIF</i>: positive • <i>IIF</i>: positive 	Treated with oral prednisone and cyclophosphamide	No
Ohata et al. ¹²	68	Right cheek	ND	Dyskeratotic acantholytic cells in infundibulum of hair follicle	<ul style="list-style-type: none"> • <i>ELISA</i>: positive for anti-desmoglein 1 antibody 	Did not receive immediate treatment and lesions spread; later treated with prednisolone 30 mg/d	Yes
Our case	19	Right cheek and temple	ND	Intercellular staining with IgG and C3	<ul style="list-style-type: none"> • <i>DIF</i>: positive • <i>ELISA</i>: negative for desmogleins 1 and 3 	Partial response to clobetasol 0.05% ointment; failure of response to dapsone 100 mg daily; prednisone 60 mg with gradual taper induced remission	No

Abbreviations: DIF, direct immunofluorescence; ELISA, enzyme-linked immunosorbent assay; IgG, immunoglobulin G; IIF, indirect immunofluorescence; ND, not determined; N/A, not available information.

refractory to appropriate antimicrobial treatment. This case exemplifies the need for proper pathological and immunopathological studies to establish a diagnosis of this very unusual variant of PF.

Ethical disclosures

Protection of human and animal subjects. The authors declare that no experiments were performed on humans or animals for this investigation.

Confidentiality of data. The authors declare that this study was carried out in accordance with the protocols of their institution concerning the publication of patient data, and that all the patients included in the study were properly informed and gave their written informed consent to participation.

Right to privacy and informed consent. The authors obtained the informed consent of the patients and/or subjects referred to in this article. The signed forms are in the possession of the corresponding author.

Conflicts of interest

The authors declare that they have no conflicts of interest.

References

1. Qian Y, Prisyanyh P, Andraca E, Qaqish BF, Aoki V, Hans-Filho G, et al. IgE, IgM, and IgG4 anti-desmoglein 1 autoantibody profile in endemic pemphigus foliaceus (fogo selvagem). *J Invest Dermatol.* 2011;131:985–7.
2. Flores G, Qian Y, Díaz LA. The enigmatic autoimmune response in endemic pemphigus foliaceus. *Actas Dermosifiliogr.* 2009;100 Suppl. 2:40–8.
3. Schwartz RA. Pemphigus foliaceus. <http://emedicine.medscape.com/article/1064019-overview#a0199> (accessed 08.12.11).
4. Lin R, Ladd Jr DJ, Powell DJ, Way BV. Localized pemphigus foliaceus induced by topical imiquimod treatment. *Arch Dermatol.* 2004;140:889–90.
5. Brenner S, Wolf R, Ruocco V. Contact pemphigus: a subgroup of induced pemphigus. *Int J Dermatol.* 1994;33:843–5.
6. Newton JA, McGibbon DH, Monk B, Rowell NR. Pemphigus foliaceus localized to the nose. *Br J Dermatol.* 1988;118:303–5.
7. Paramsothy Y, Lawrence CM. 'Tin-tack' sign in localized pemphigus foliaceus. *Br J Dermatol.* 1987;116:127–9.
8. Yamamoto S, Kanekura T, Gushi A, Sekiyama M, Shimada T, Shimada K, et al. A case of localized pemphigus foliaceus. *J Dermatol.* 1996;23:893–5.
9. Termeer CC, Technau K, Augustin M, Simon JC. Topical tacrolimus (protopic) for the treatment of a localized pemphigus foliaceus. *J Eur Acad Dermatol Venereol.* 2004;18:636–7.
10. Kishibe M, Kinouchi M, Ishida-Yamamoto A, Koike K, Lizuka H. Pemphigus foliaceus localized to the nose. *Clin Exp Dermatol.* 2003;28:560–2.
11. Zaraq I, El Euch D, Kort R, Sellami M, Mokni M, Makni S, et al. Localized pemphigus: a report of three cases. *Int J Dermatol.* 2010;49:715–6.
12. Ohata C, Akamatsu K, Imai N, Sumimura Y. Localized pemphigus foliaceus exclusively involving the follicular infundibulum: a novel peau d'orange appearance. *Eur J Dermatol.* 2011;21:392–5.
13. Amagai M, Komai A, Hashimoto T, Shirakata Y, Hashimoto K, Yamada T, et al. Usefulness of enzyme-linked immunosorbent assay using recombinant desmogleins 1 and 3 for serodiagnosis of pemphigus. *Br J Dermatol.* 1999;140:351–7.
14. Ishii K, Amagai M, Hall RP, Hashimoto T, Takayanagi A, Gamou S, et al. Characterization of autoantibodies in pemphigus using antigen-specific enzyme-linked immunosorbent assays with baculovirus-expressed recombinant desmogleins. *J Immunol.* 1997;159:2010–7.
15. Groves RW. Pemphigus: a brief review. *Clin Med.* 2009;9:371–5.